



## Brace and core stabilization to decrease vertebral curve in scoliosis cases scoliometer parameter and taps: a case study

Andrew Wijaya Saputra<sup>1\*</sup>, Ruth Golda Meir<sup>2</sup>, Riza Pahlawi<sup>2</sup>

### ABSTRACT

**Introduction:** Scoliosis is a disorder characterized by lateral curvature and rotation of the spine. The initial phase begins with a triggering event during the growth period. Characteristics that can be seen in scoliosis patients are differences in posture on the right and left sides, the rotation of the spine, the presence of hump, and other complications, namely pain and tightness.

**Methods:** This study was a case study with a brace method accompanied by CSE, which was carried out for approximately three months with an intensity of exercise 2 times a week and a home exercise program. The modified Borg scale measures shortness of breath. Pain is calculated using a visual analog scale. While scoliosis disorders are measured using two tools, namely the scoliometer and the Trunk Appearance Perception Scale (TAPS).

**Results:** Using objective parameters, namely the scoliometer. The degree of a scoliosis curve decreases in the thoracic part, with the initial value at 10° to 7°. Then there is no significant reduction in the lumbar region, with the initial interpretation at 6° and back to 6°. The result obtained through TAPS is also a stagnant number which is interpreted as no change in numbers too large or small, which means that the patient does not feel any significant changes in posture after going through an exercise program.

**Conclusions:** It can be concluded that there was a change in the scoliosis curve of the thoracic part by giving a brace accompanied by core stability exercises. However, this technique was less effective in the lumbar area. Behind that, when viewed during activities, patients felt a decrease in the intensity of tightness and pain.

**Keywords:** brace, core stabilization exercise, decrease vertebral curve, scoliometer, scoliosis, TAPS.

**Cite this Article:** Saputra, A.W., Meir, R.G., Pahlawi, R. 2023. Brace and core stabilization to decrease vertebral curve in scoliosis cases scoliometer parameter and taps: a case study. *Physical Therapy Journal of Indonesia* 4(1): 55-59. DOI: [10.51559/ptji.v4i1.76](https://doi.org/10.51559/ptji.v4i1.76)

### INTRODUCTION

Scoliosis is a 3D (three-dimensional) deformity or abnormality characterized by lateral curvature and spinal rotation. Scoliosis generally has two main types that are distinguished based on the age of onset: adolescent idiopathic Scoliosis (AIS) and adult degenerative scoliosis (ADS).<sup>1</sup>

Biomechanical theories regarding changes in posture explained by Stoke's vicious pathogenesis cycle have 4 phases of Scoliosis. The initial phase begins with a triggering event during the growth period. The spinal curvature phase causes changes in body posture due to asymmetric loading on the vertebrae. In the third phase, namely the spinal deformity, there is already a change in the oblique body shape and will continue into the progression phase.<sup>2</sup>

The highest incidence of Scoliosis at the age of 4 months to 79 years was idiopathic Scoliosis, with a presentation of 74.7%, and non-idiopathic Scoliosis, with 25.3%. Data from The National Scoliosis Foundation USA says that cases of Scoliosis are found in 4.5% of the general population in the world today. Scoliosis data originating from Korea shows that out of 269,376 cases of Scoliosis, there

are 234,446 cases of adolescent Scoliosis with an age range of 10-19 years. Where scoliosis incident in Indonesia does not yet have an exact number.<sup>2,3</sup>

Idiopathic Scoliosis is classified into three based on the age range, namely infantile idiopathic Scoliosis if the age is under two years. Juvenile Idiopathic Scoliosis if it is between the ages of 3 to 9 years, and the most common Adolescent Idiopathic Scoliosis if it is between the ages of 10 to 19. Characteristics that can be seen in scoliosis patients are differences in posture on the right and left sides, the rotation of the spine, the presence of hump, and other complications, namely pain and tightness. Spinal abnormalities trigger these things due to Scoliosis.<sup>3</sup>

Core stability exercise is a physiotherapy intervention with isometric contractions to increase muscle strength and central/trunk stability by activating and stabilizing muscles.<sup>4</sup> The use of a brace accompanied by core stabilization exercise (CSE) includes pelvic tilt, cat-camel pose, basic trunk curl (crunch), bridge (with knee extension), double-leg abdominal press, superman, arm/leg raise, quadruped arm/leg elevation and hand walkout are effective in reducing the degree of scoliosis curve and increasing lumbar muscle

<sup>1</sup>Physiotherapy study program, Politeknik Kesehatan Hermina, Jakarta, Indonesia;

<sup>2</sup>Physiotherapy study program, Universitas Indonesia, Depok, Indonesia;

\*Corresponding to:

Andrew Wijaya Saputra;  
Physiotherapy Study Program,  
Politeknik Kesehatan Hermina,  
Jakarta, Indonesia;  
[andrew.wijaya@poltekkeshhermina.ac.id](mailto:andrew.wijaya@poltekkeshhermina.ac.id)

Received : 2023-03-16

Accepted : 2023-04-26

Published : 2023-05-15

strength.<sup>5</sup> In addition, the merger of these two methods effectively improves spine stabilization and reduces postural changes by building increased flexibility and muscle strength.<sup>6-8</sup>

Two assessments are applied: the scoliometer as an objective parameter and TAPS as the subjective parameter. A scoliometer is a measurement test performed by a physiotherapist using a tool. The mechanism of action is with the patient doing Adam's Forward Bending Test, then the instrument is placed and moved along the spine.<sup>9</sup> While TAPS is three images that describe the torso from 3 points of view. TAPS parameters are obtained from the patient's self-image.<sup>10,11</sup>

In this case, education on braces and core stabilization exercises is to reduce the degree of a scoliosis curve in adolescents. So this study was made to explain to the reader the effectiveness of the brace accompanied by core stabilization exercise against decreasing the scoliosis curve measured by the parameters of the scoliometer and TAPS.

## METHODS

This study was a case study with a brace method accompanied by CSE, which was carried out for approximately three months with an intensity of exercise 2 times a week and a home exercise program. The criteria are taken; the patient was 14 years old with non-structural thoracolumbar Scoliosis, Cobb angle 16.9, and accompanied by complaints of pain and tightness. Another inclusion criterion is to use a brace for 22 hours in less than a year. Operative actions are excluded. All participants explained the study process and were given an informed consent sheet once they agreed to participate.

## Measuring instrument

The modified Borg scale measures shortness of breath subjectively based on patient complaints through a scale of 0-10. Pain is measured through questions about pain experience using a visual analog scale ranging from 0-10. While scoliosis disorders are measured using two tools, namely the scoliometer and the Trunk Appearance Perception Scale (TAPS).

## Intervention

Rehabilitation in the form of applied interventions aims to reduce the complaints that patients experience. The interventions provided in the form of CSE were accompanied by several other supporting exercises, such as Breathing exercises with the 3D breathing exercise method and diaphragmatic Breathing, with each movement having a daily frequency and intensity according to patient tolerance and 10 minutes. The practices aim to reduce shortness complaints, with the doses listed in Table 1. The main exercise, namely the core stabilization exercise, is applied with training components such as a Superman pose, bird dog exercise, camel pose, plank, and pelvic tilt.

The reason for giving other exercises besides CSE is to prepare the patient's body before receiving the primary practice. This exercise is where stretching can increase muscle flexibility before receiving CSE. Breathing exercises are intended for complaints of patient tightness due to suppression of the lungs due to Scoliosis with the mechanism of action by developing rib cages in 3D in patients.<sup>12</sup> For the reason given, massage is a muscle release. These exercises are grouped based on the rehabilitation

**Table 1. Physiotherapy Intervention Dose.**

Type	Method	Dose	Description
Breathing Exercise	3D Breathing	F: Everyday I: Patient tolerance Ti: 10 minutes	To help improve pulmonary function and decrease Cobb angle.
	Diaphragmatic Breathing	F: Everyday I: Patient tolerance Ti: 10 minutes	To reduce shortness of breath.
Massage	Effleurage	F: 1x/ week I: 5 minutes Ty: Effleurage	To give a relaxing effect on muscle spasms.
Exercise Therapy	Stretching Exercise	F: Everyday I: Patient tolerance Ti: 10 minutes Ty: Active stretching	To stretch tense muscles and prepare the body for the next exercise.
	Core Stabilization	F: 2x/ week I: 5reps, 8secs Ti: 10 minutes Ty: Superman pose, bird dog, cat camel, plank, pelvic tilt	Effective for lowering the Cobb angle, keeping a neutral position on the spine, and increasing the strength of the thoracolumbar muscles.

F, frequency; I, intensity; Ti, time; Ty, type.

phase listed in Table 2.

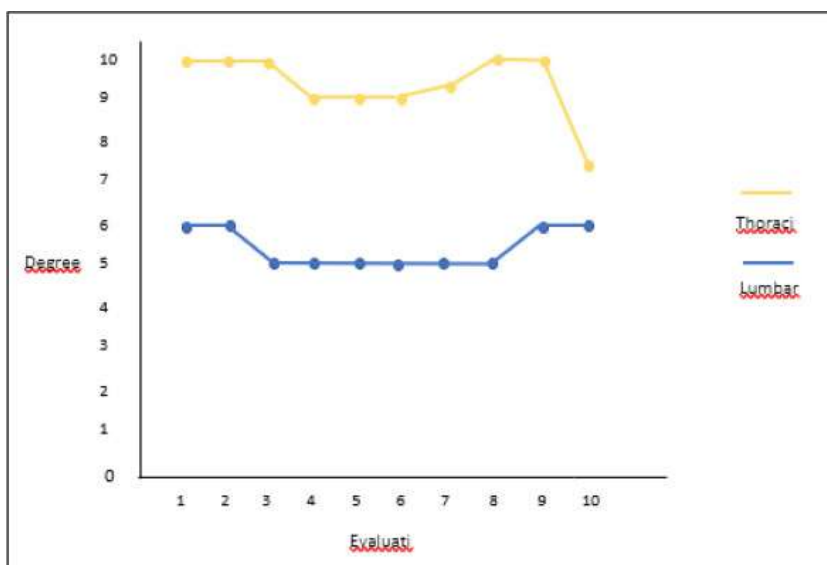
Table 2 shows that not all exercises are applied in one phase but are carried out in up to 10 stages in

**Table 2. Exercise phase.**

Phase	Breathing exercise	Massage	Stretching	Core stabilization exercise
1	✓		✓	
2	✓		✓	✓
3	✓	✓	✓	✓
4		✓	✓	✓
5		✓	✓	✓
6		✓	✓	✓
7			✓	✓
8		✓	✓	✓
9			✓	✓
10			✓	✓

**Table 3. Interpretation of the trunk appearance perception scale (TAPS) evaluation results.**

Evaluation	Set		
	1	2	3
1	4	3	4
2	4	3	4
3	4	3	4
4	4	3	4
5	3	3	3
6	3	3	3
7	3	2	3
8	3	2	3
9	3	2	3
10	3	2	4



**Figure 1.** The results of vertebral measurements using a scoliometer.

about three months. Consideration of the provision of practices is based on the patient’s complaints in that phase. It can be seen that some exercises arise again, namely, massage, starting to disappear, breathing exercises and settling, stretching, and core stability.

The reason for the loss of breathing exercises is that the patient no longer complains of shortness of breath during or without doing activities. Then the reason for the re-provision of massage therapy is that patients often experience dull pain in the m.upper trapezius sinistra due to spasms during online school activities. Then the administration of stretching and core stability exercises is consistently given because these exercises are the main topic of the author to find out their effectiveness against decreasing the degree of curve in cases of Scoliosis.

**RESULTS**

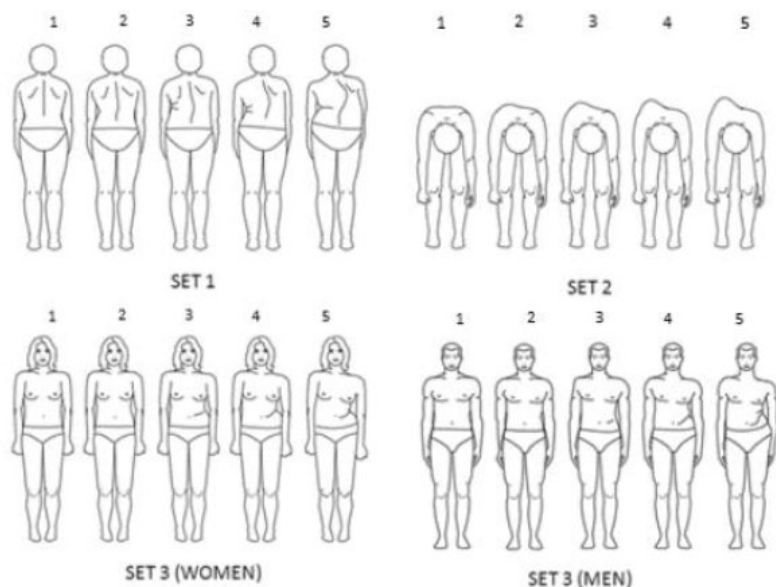
Researchers found the evaluation results using objective parameters, namely the scoliometer. Fluctuating results were obtained, as shown in Figure 1. The degree of a scoliosis curve decreases in the thoracic part, with the initial value at 10° to 7°. Then there is no significant reduction in the lumbar region, with the initial interpretation at 6° and back to 6°.

Then the subjective examination, namely by using taps parameters, depicts the same body shape as the results listed on the scoliometer. The TAPS evaluation is formed into a table containing evaluations 1 to 10 with three sets, as shown in Figure 2 and the interpretation in Table 3.

The result obtained through TAPS is an increase interpreted by the smaller number issued. This assessment leads to the patient’s self-view or image of himself starting to improve due to changes in posture that are getting better. However, there is also a stagnant number interpreted as no change in numbers too large or small, which means that the patient does not feel any significant changes in posture after an exercise program. Furthermore, the increasing numbers are interpreted as a decrease, indicating the lack of effectiveness of the exercise program.

**DISCUSSION**

The administration of rehabilitation methods using a brace is very effective if it is affected by the patient’s adherence to the use time. It is also recommended to wear a brace for a whole day every day. The mount can be used at the desired time, for example, only at night but only intended for single curves, and in double curves, it is recommended to use the brace throughout the day. However, braces



**Figure 2.** Trunk appearance perception scale (TAPS)

are less effective in thoracolumbar scoliosis patients than in thoracic Scoliosis due to stiffness in the ribs that are difficult to correct.<sup>13,14</sup>

On An. AN, who has thoracolumbar Scoliosis, obtained the result that using a brace throughout the day for approximately three consecutive months decreased degrees in the thoracic curve. The curative effect in the brace generally decreases with increasing maturity.<sup>15</sup> Since the results of brace application in patients with Scoliosis are dependent on the in-brace correction and the brace wearing time (compliance), the results with high-quality braces seem to be the best in immature patients, as their curvatures can be corrected more easily.<sup>16,17</sup>

Furthermore, the CSE method effectively controls movements to maintain the spine's neutral position and increase the lumbar muscles' strength. Other studies have also mentioned that CS exercises effectively reduce Cobb's angle.<sup>5,18</sup> Core stabilization is an exercise approach involving trunk muscles, i.e., the musculature of the spine, pelvis, and abdomen regions, recently used to improve body balance and reduce postural asymmetries.<sup>19</sup>

Indeed, core stabilization exercises recruit spinal stabilizer muscles, which improve the ability to straighten the spine.<sup>20</sup> The core muscles limit the forces of compression, distortion, and spine rotation. Although core stabilization exercises would appear to be adequate to increase muscle strength of the lumbar region and improve neuromuscular imbalance, which represents the causes of IS, few studies have investigated the beneficial effects of core stabilization exercises in subjects with IS.<sup>21</sup>

An. AN performed CSE for approximately three months of exercise intensity two times a week, and

a daily exercise program at home found effective results in decreasing the degree of the thoracic curve. Combining these two methods, namely, brace, and CSE, by using the assessment parameters of the scoliometer and TAPS, it was produced that there was a decrease in the degree of the thoracic curve and the absence of a reduction in the degree of the lumbar curve.

This study has several limitations that need to be considered. First, the design of this study is a case study, so it cannot be generalized to all conditions of patients with Scoliosis. Second, the research was carried out for approximately three months due to limited research time and the inability to evaluate the therapy's long-term effects.

## CONCLUSION

After being evaluated ten times, results were obtained as a decrease in the scoliosis curve, assessed using the scoliometer parameter as an objective, and TAPS as a subjective measuring tool. It can be concluded that there is a change in the scoliosis curve of the thoracic part by giving a brace accompanied by core stability exercise. However, this technique is less effective in the lumbar area. Behind that, when viewed during activities, patients feel a decrease in the intensity of tightness and pain.

## CONFLICT OF INTEREST

This study does not have any conflict of interest.

## ETHICAL CONSIDERATION

The authors obtained informed consent that the sample had been approved before conducting the study.

## FUNDING

This study received no grant from any institution.

## AUTHOR CONTRIBUTION

AWS conceived the study design, collected and analyzed the data, and drafted the manuscript; RGM and RP interpreted the data analysis and drafted the manuscript.

## REFERENCES

1. Janicki JA, Alman B. Scoliosis: Review of diagnosis and treatment. *Paediatr Child Health* 2007; 12: 771–776.
2. Lukman J. Uji sensitivitas dan spesifitas adam's forward bending test terhadap skoliometer untuk deteksi dini asimetri trunkus pada Mahasiswa Fakultas Kedokteran UIN Syarif Hidayatullah Jakarta. 2018.
3. Baswara CGPK, Weta IW, Ani LS. Deteksi dini skoliosis di tingkat Sekolah Dasar Katolik Santo Yoseph 2. *Intisari Sains Medis* 2019; 10. doi:10.15562/ISM.V10I2.185.

4. Denny Pratama A, Muhamad Elfitra Salam. The effectiveness of core stability exercise to improve functional ability in a lumbar herniated nucleus pulposus patient: A Case Study. *Physical Therapy Journal of Indonesia* 2021; 2: 61–66.
5. Ko KJ, Kang SJ. Effects of 12-week core stabilization exercise on the Cobb angle and lumbar muscle strength of adolescents with idiopathic Scoliosis. *J Exerc Rehabil* 2017; 13: 244–249.
6. Yagci G, Yakut Y. Core stabilization versus scoliosis-specific exercises in moderate idiopathic scoliosis treatment. *Prosthet Orthot Int* 2019; 43: 301–308.
7. Ibrahim Elsayed Aly M, Seddik Amin F, Abdelmonem Negm M, Attyah Mohamed Diab A. Effect of integrated exercise program on posture in adolescent Idiopathic Scoliosis (case study). 2019. doi:10.1016/S0025-6196(12)65233-1.
8. Tolo VT, Herring JA. Scoliosis-specific exercises: A state of the Art Review. *Spine Deform* 2020; 8: 149–155.
9. Nabila E. Efektivitas Skoliometer Sebagai Alat Deteksi Dini Skoliosis. *Health and Medical Journal* 2020; 2: 58–61.
10. Bago J, Matamalas A, Sánchez-Raya J, Pellise F, Pérez-Grueso FJS. Responsiveness of Image Perception Outcome Scales After Surgical Treatment of Idiopathic Scoliosis: A Comparison Between the Trunk Appearance Perception Scale (TAPS) and Scoliosis Research Society-22 (SRS-22) Questionnaire. *Spine Deform* 2018; 6: 417–423.
11. Bago J, Sanchez-Raya J, Perez-Grueso FJS, Climent JM. The Trunk Appearance Perception Scale (TAPS): a new tool to evaluate the subjective impression of trunk deformity in patients with idiopathic Scoliosis. *Scoliosis* 2010; 5. doi:10.1186/1748-7161-5-6.
12. Lee H-J, Lee S-M. Effects of Schroth exercise therapy on curvature and body appearance of patients with idiopathic lumbar Scoliosis. *Physical Therapy Rehabilitation Science* 2020; 9: 230–237.
13. Karimi MT, Rabczuk T, Kavyani M, Macgarry A. Evaluation of the efficacy of part-time versus full-time brace wear in subjects with adolescent idiopathic Scoliosis (AIS): A literature review. *Curr Orthop Pract* 2019; 30: 61–68.
14. Ruffilli A, Fiore M, Barile F, Pasini S, Faldini C. Evaluation of night-time bracing efficacy in treating adolescent idiopathic Scoliosis: a systematic review. *Spine Deform* 2020; 9: 671–678.
15. Aulisa AG, Guzzanti V, Falciglia F, Giordano M, Galli M, Aulisa L. Brace treatment of idiopathic Scoliosis is effective for a curve over 40 degrees, but is the evaluation of Cobb angle the only parameter for the indication of treatment? *Eur J Phys Rehabil Med* 2018; 55. doi:10.23736/S1973-9087.18.04782-2.
16. van den Bogaart M, van Royen BJ, Haanstra TM, de Kleuver M, Faraj SSA. Predictive factors for brace treatment outcome in adolescent idiopathic Scoliosis: a best-evidence synthesis. *Eur Spine J* 2019; 28: 511–525.
17. Xu L, Qin X, Qiu Y, Zhu Z. Initial Correction Rate Can Predict the Outcome of Brace Treatment in Patients With Adolescent Idiopathic Scoliosis. *Clin Spine Surg* 2017; 30: E475–E479.
18. Dimitrijević V, Viduka D, Šćepanović T, Maksimović N, Giustino V, Bianco A *et al.* Effects of Schroth method and core stabilization exercises on idiopathic Scoliosis: a systematic review and meta-analysis. *European Spine Journal*. 2022; 31: 3500–3511.
19. Ayhan C, Unal E, Yakut Y. Core stabilization reduces compensatory movement patterns in patients with injury to the arm: a randomized controlled trial. *Clin Rehabil* 2014; 28: 36–47.
20. Gür G, Ayhan C, Yakut Y. The effectiveness of core stabilization exercise in adolescent idiopathic Scoliosis: A randomized controlled trial. *Prosthet Orthot Int* 2017; 41: 303–310.
21. Ko KJ, Kang SJ. Effects of 12-week core stabilization exercise on the Cobb angle and lumbar muscle strength of adolescents with idiopathic Scoliosis. *J Exerc Rehabil* 2017; 13: 244–249.



This work is licensed under a Creative Commons Attribution